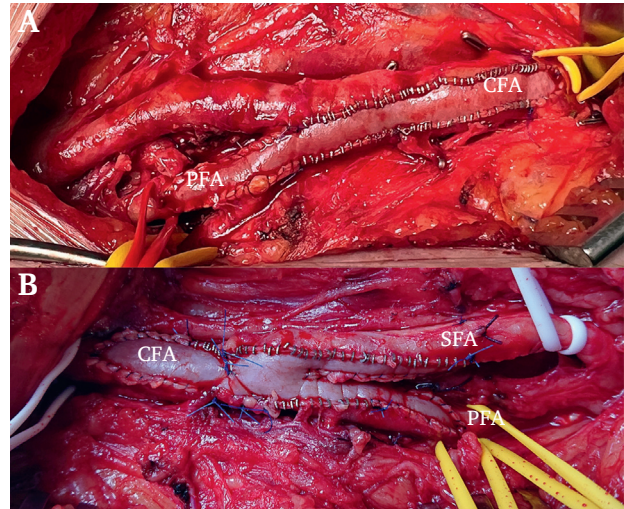


## IMAGE

### Stitching at a Good Clip: A Renewed Look at Stapled Vascular Anastomoses

Stapled vascular anastomoses are recognised to reduce neointimal hyperplasia and thus anastomotic stenosis following renal access surgery but are not often used beyond this scope. They can be useful in reducing suturing time in some typical anastomoses, especially when a long suture line is anticipated, exemplified here by a simple patch used during femoral endarterectomy with profunda-plasty (A) or a more elaborate Y patch used to extend from the common femoral (CFA) to both the superficial femoral (SFA) and profunda femoris (PFA) arteries (B). It is important to use the smaller but more secure medium sized clips (rather than the large sized ones that are too loose in this scenario), exemplified here using the AnastoClip AC System (Le Maitre Vascular, Hereford, UK). The curved sections and apices of the anastomoses are typically sutured with polypropylene, while the straight sections are then anastomosed using the clips, taking care to evert the edges.



Arindam Chaudhuri  
Bedfordshire — Milton Keynes Vascular Centre, Bedford  
Hospital NHS Trust, Kempston Road, Bedford MK42 9DJ, UK  
Email-address: [a.chaudhuri@ntlworld.com](mailto:a.chaudhuri@ntlworld.com),  
[@vascularis](https://twitter.com/vascularis)

© 2022 The Author. Published by Elsevier Ltd on behalf of  
European Society for Vascular Surgery. This is an open  
access article under the CC BY-NC-ND license (<http://creativecommons.org/licenses/by-nc-nd/4.0/>).

<https://doi.org/10.1016/j.ejvsf.2022.11.001>